



**PATIENT**

Koda Scott

**PRESENTING CLINICAL SIGNS**

History: Grade III/VI heart murmur since a puppy. No clinical signs. Pre surgical echo for castration.

**SPECIES**

Canine

**ECHOCARDIOGRAM FINDINGS**

2D, m-mode, color flow and doppler imaging is available. Normal MV leaflets with no obvious prolapse. No mitral regurgitation. Normal left atrial dimension. Normal LV diameter with adequate myocardial function. Normal LV wall dimensions. The tricuspid valve appears subjectively normal, trace tricuspid regurgitation. The right heart is normal. No overt evidence of pulmonary arterial hypertension. The pulmonic and aortic valves are normal in morphology and mobility. No obvious aortic abnormalities identified, however the LVOT velocity is mildly elevated. Laminar flow. Pulmonic outflow velocities are normal. No aortic or pulmonic insufficiency. No obvious congenital shunts. No pericardial or pleural effusion noted. No cardiac tumors observed.

**BREED**

Old English Sheepdog  
Mix

**SEX**

Male

**CARDIAC CHART**

**AGE**

12 months

**WEIGHT**

60.6lbs

**INTERPRETED BY**

Maggie Machen Lamy,  
DVM, DACVIM  
(Cardiology)

**IMAGING PERFORMED BY**

Mark van Campen,  
DVM

**HOSPITAL NAME**

Mississippi Hills  
Animal Hospital

**REFERRING VET**

Dr. van Campen

**INVOICE**

27808

**DATE**

12.5/22

CANINE CARDIAC PARAMETERS	MR VMAX (m/s)	TR VMAX (m/s)	LA/AO (Boon method)	LA/AO (Heart Base; Swe)	FS (%)	EF (%)	EPSS (cm)
<b>NORMAL PARAMETER</b>	4.5-5.5	<2.7	1.3	<1.6	28-40	40-100	<0.6
<b>PATIENT</b>	NA	NM	NM	1.3	31	60	0.6
CANINE CARDIAC PARAMETERS	HR (BPM)	AV VMAX (m/s)	PV MAX (m/s)	BODY WEIGHT (kg)	LA 2D short axis Base view (cm)	LVIDd Avg; 2D and m-mode short axis (cm)	LVIDs Avg; 2D and m-mode short axis (cm)
<b>NORMAL PARAMETER</b>	50-100	0.7-1.7	0.7-1.6	BELOW	BELOW	BELOW	BELOW
<b>PATIENT</b>	NM	2.5	1.4	27.5	3.2	4.5	3.1
*Normal chamber parameters expressed as a mean value (SD)				3	1.27 (5.3)	2.46 (2.46)	1.36 (5.5)
<b>BODY WEIGHT DEPENDENT PARAMETERS</b>				5	1.40 (4.5)	2.74 (5.2)	1.60 (4.7)
<i>*Note: All measurements based upon multi-modal images and methods. An average value is reported.</i>				10	1.50 (3.8)	3.27 (3.5)	2.06 (3.1)
				15	1.83 (2.0)	3.71 (2.4)	2.43 (2.1)
				20	2.02 (1.9)	4.14 (2.2)	2.80 (2.0)
				25	2.18 (2.4)	4.48 (2.9)	3.10 (2.5)
				30	2.33 (3.3)	4.83 (3.9)	3.39 (3.4)
				35	2.48 (4.3)	5.17 (5.0)	3.69 (4.5)
				40	2.62 (5.2)	5.48 (6.1)	3.96 (5.4)
				50	2.88 (7.1)	6.07 (8.3)	4.46 (7.4)

**INTERPRETATION OF THE FINDINGS & FURTHER RECOMMENDATIONS**

The only cause of a murmur identified is mildly increased flow velocity through the aortic root. No obvious aortic valve abnormalities visualized and there is no subaortic ridge seen. In the absence of structural abnormalities this is considered a benign flow murmur. This type of outflow abnormality is heart rate dependent and will vary with hydration/volume changes as well. No obvious congenital shunts or defects are observed in this study; however, it is important to note that small abnormalities are easily missed without advanced diagnostics.

No cardiac medications are indicated at this time. Monitor for any development of cough, labored breathing or exercise intolerance.



**PATIENT**

Koda Scott

No cardiac contraindication for general anesthesia is seen.

**SPECIES**

Canine

Assuming the murmur persists, recommend recheck echocardiogram in 6-12 months to ensure no progressive issues are seen, sooner if any clinical signs arise in the interim.

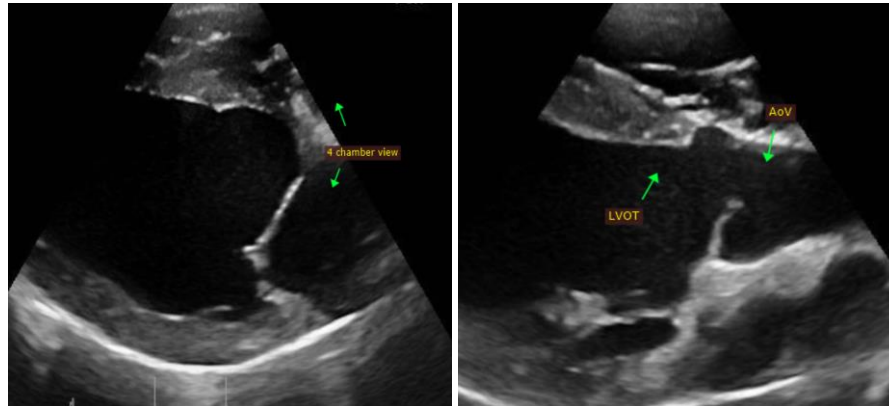
**BREED**

Old English Sheepdog  
Mix

**IMAGES**

**SEX**

Male



**AGE**

12 months

The information and recommendations provided are based on the images presented by the referring veterinarian. No evaluation can be communicated regarding pathology that was not visible in the image/video clips provided.

**WEIGHT**

60.6lbs

Thank you for this referral. This report was generated using transcription software, and minor dictation errors may be present. If the clinical or image interpretation does not parallel your findings or if I can be of any further assistance, please contact me.

**INTERPRETED BY**

Maggie Machen Lamy,  
DVM, DACVIM  
(Cardiology)

**Maggie Machen Lamy, DVM**  
Diplomate of the American College of Veterinary Internal Medicine (Cardiology)  
info@sonopath.com

**IMAGING PERFORMED BY**

Mark van Campen,  
DVM

**HOSPITAL NAME**

Mississippi Hills  
Animal Hospital

**REFERRING VET**

Dr. van Campen

**INVOICE**

27808

**DATE**

12.5/22